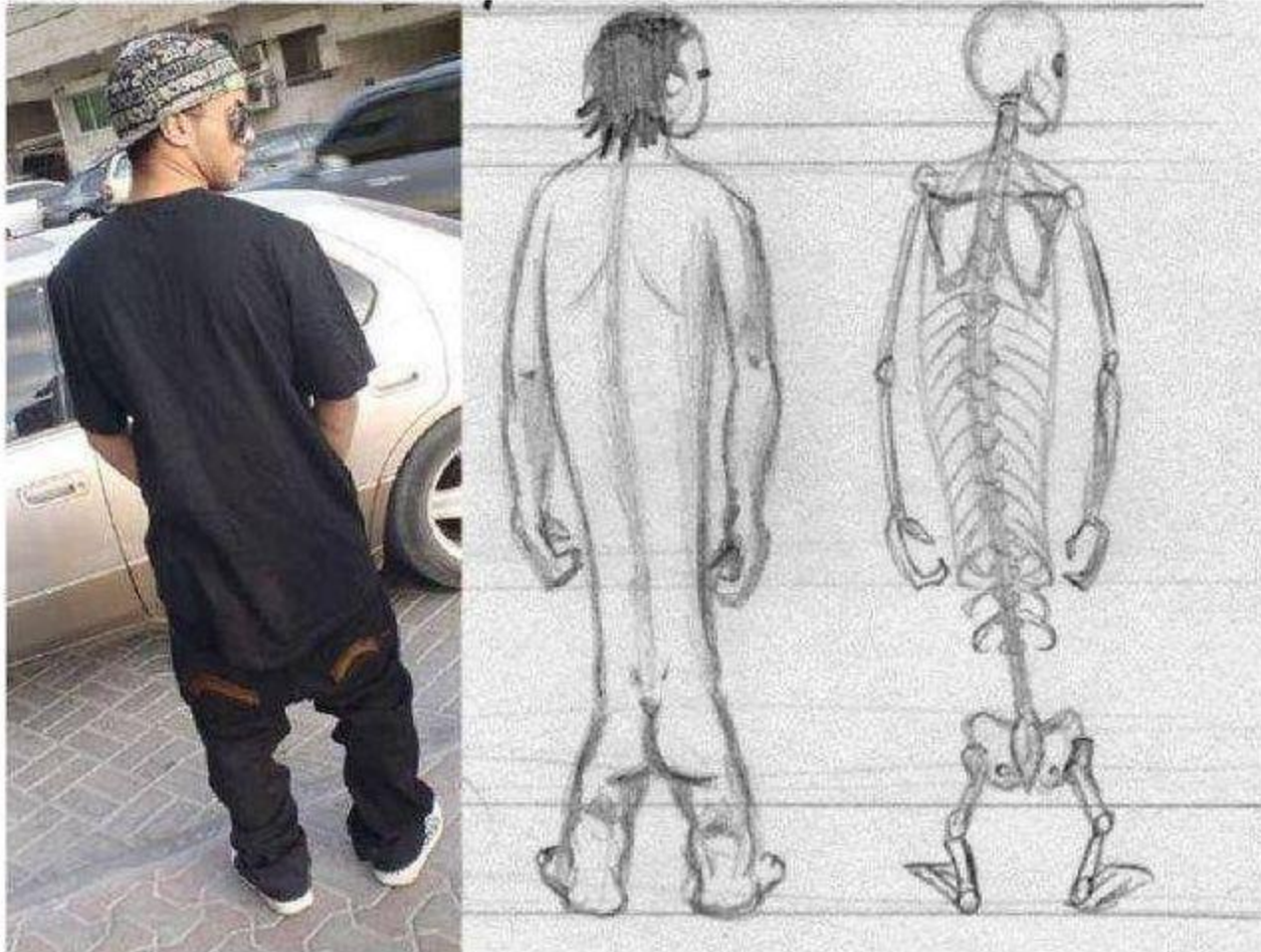


Sexuality and Body Image In Male Cancer Patients

Chris Atkinson

"Homo slackass-erectus"



Sexuality and Body Image In Young Men with Testis Cancer

- Fertility
 - Often oligo or azospermic at presentation
 - Sperm storage
- No erectile dysfunction
- Common request for prosthetic testis
- Existential recovery
- Living with cancer

Sexuality and body image In Older Men with Cancer

- hetero gay bi
- partnered or not
- sexual activity
- family/societal support
- empathetic cancer team

Sexuality and Body Image in Men with Prostate Cancer

- erectile dysfunction
- altered bowel habit
- urinary incontinence

- weight gain
- muscle bulk loss
- smaller penis
- osteopaenia
- fatigue
- flushes
- short fuse

“Statue of Drunken Hercules”



Clinical Case

- T2b. Gleason 4+3 prostate cancer
- Neoadjuvant Goserelin for 6 months
- Radiation treatment to prostate
- Further 12 months of Goserelin
- PSA now unrecordable
- Slow rise in PSA to mid normal range as testosterone recovers over 24 mths
- At three years after presentation:

David

- David (70) has poor erectile function but his wife of 45 yrs, Margaret is unconcerned

David says he misses it but “they have had a good run”
“viagra not worth the expense”

Margaret says “the cuddles are better”

Clinical Case

- T2b. Gleason 4+3 prostate cancer
- Neoadjuvant goserelin for 6 months
- Radiation treatment to prostate
- Further 12 months of goserelin
- PSA now unrecordable
- Slow rise in PSA to mid normal range as testosterone recovers over 24 mths
- At three years after presentation:

Roger

- Roger(55) has poor erectile function and little desire.
 - His wife Jane thinks his lack of interest means he is “having an affair”
 - Roger hopes that if desire returns, his marriage, that he wants to work, will endure

Clinical Case

- T2b. Gleason 4+3 prostate cancer
- Neoadjuvant goserelin for 6 months
- Radiation treatment to prostate
- Further 12 months of goserelin
- PSA now unrecordable
- Slow rise in PSA to mid normal range as testosterone recovers over 24 mths
- At three years after presentation:

John

Roger (55) is gay and not partnered

- His only support systems (after his Mother died) are around gay clubs, and his lack of desire, poor erectile function and “fatness” means he is “not desirable”
- He cannot maintain company/support
- He feels isolated and depressed

Sexuality and Body Image in Older Men

- Knowledge of the true picture
 - takes time
 - requires trust
 - demands privacy
 - needs RESOURCE

Personalised Care in Prostate Cancer

- The Right Treatment, for the Right Patient at the Right Time
- Does not mean Abiraterone or targeted drugs
- But access to psycho-social, sexual healing and existential care